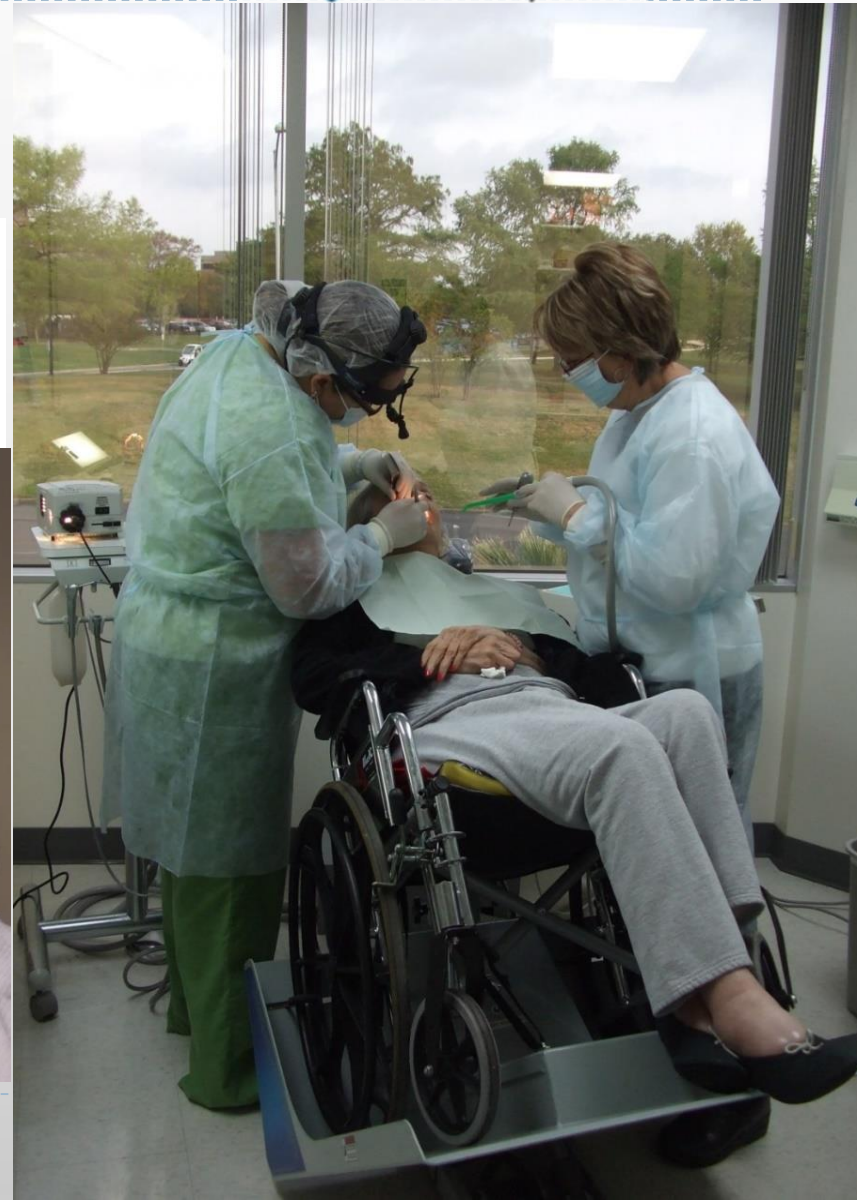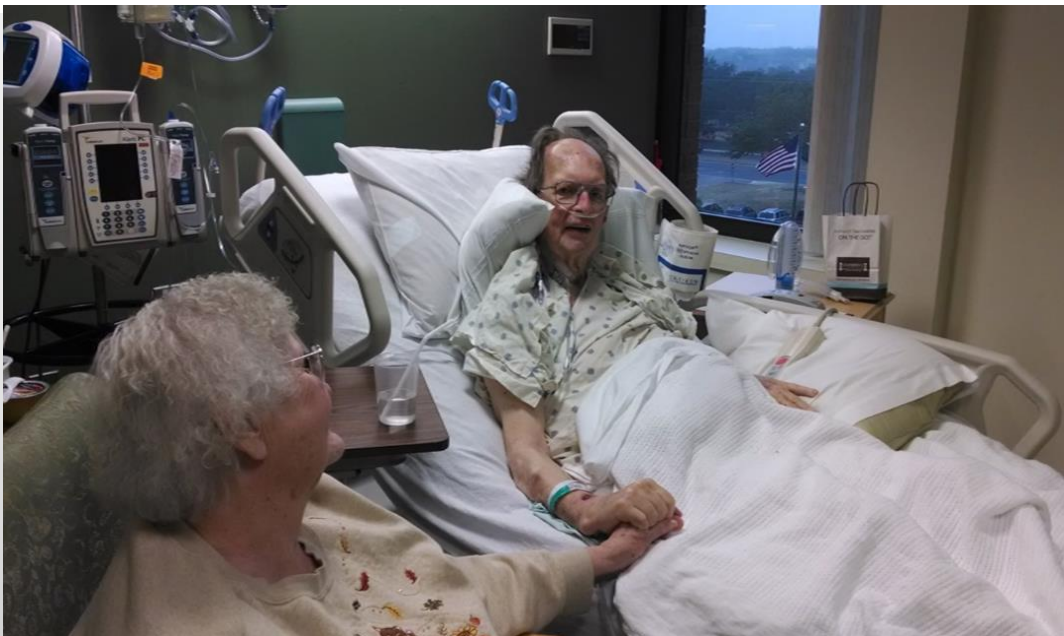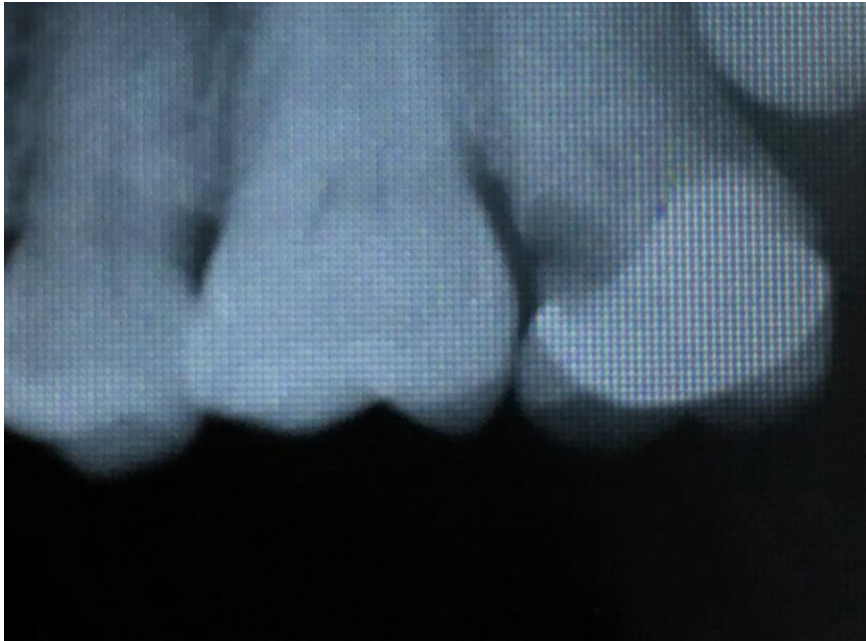


Sarah Dirks, DDS



Geriatric Case Study:

What would you recommend for #15?
How would you decide?



Note: What option should always be considered & presented?

Traditional:

- RCT?/Buildup/Crown?
- Resin Glass Ionomer?
- Silver Glass Ionomer?
- Packable Resin?
- Amalgam?
- Extraction?
- Extraction + implant?

MID:

- Monitor?
- ART?
- SDF?
- "SMART"?

Multidimensional Assessment & Document

Patient Factors:

- ❑ Ability to tolerate care?
- ❑ Medical status?
- ❑ Medications?
- ❑ Ability to pay?
- ❑ Bed ridden? Can transfer?
- ❑ Oral hygiene status?
- ❑ Caries risk?
- ❑ Pt age?

Tooth & TX Factors:

- ❑ Importance of specific tooth?
- ❑ Anterior vs posterior tooth?
- ❑ Access to tooth?
- ❑ Moisture control?
- ❑ Treatment location?
- ❑ Caries extent? # of caries?



2 Major Pragmatic MID Concerns: Geriatric Patients

1. Reimbursement Realities

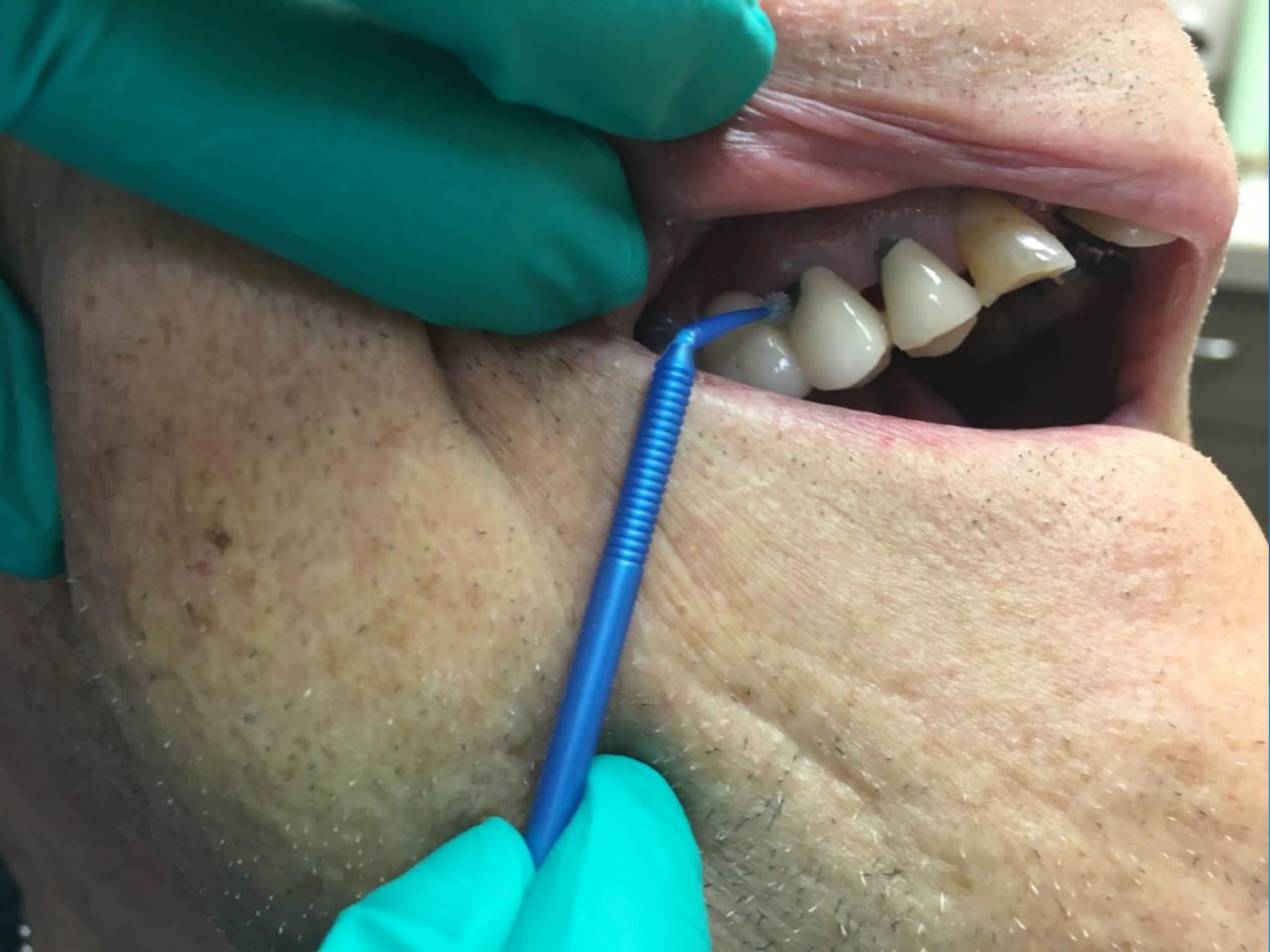- ❑ No consistent reimbursement consensus yet, but.....
- ❑ Daily per diem versus % of production
- ❑ Reapplication

2. Restoration choice and food traps

▶ D1354: Interim caries arresting medicament application

Conservative tx of an active, non-symptomatic carious lesion by topical application of a caries arresting or inhibiting medicament and without mechanical removal of sound tooth structure.

- ▶ Given the totality of circumstances - strive to “do the right thing” in the “best *interest of the patient*”



Teledentistry in a Geriatric Mobile Dental Private Practice

▶ The Good, the Bad, and the Unexpected:

- ❑ Ultimate Goals?
- ❑ “TOE” exam = Teledentistry Oral Exam
 - photos X 16
 - List of “other information” regarding pt specifics
- ❑ Pilot versus protocol?
- ❑ Synchronized versus not synchronized
- ❑ Multidimensional patient assessment: Geriatrics